



Peripheral Facial Nerve Paralysis Secondary to Acute Otitis Media

Akut Otitis Mediaya Sekonder Gelişen Periferik Fasiyal Paralizi

Facial Nerve Paralysis

Ahmet Mutlu¹, Murat Ozturk¹, Murat Topdag¹, Mete Iseri², Sinem Dasli³

¹Department of Otolaryngology, Kocaeli University Faculty of Medicine, ²KBB Akademi Grup,

³Kocaeli Derince Training and Research Hospital, Kocaeli, Turkey

This study is presented at 2nd Otolology and Audiology Symposium of Baskent University on 5-6th of June 2015, Ankara, Turkey.

Özet

Amaç: Akut otitismedia çocukluk çağında oldukça sık görülen bir hastalık olmakla birlikte buna eşlik eden periferikfasiyal sinir paralizi oldukça dramatik bir klinik durumdur. Bu çalışmada akut otitismediayasekonder gelişen fasiyal sinir paralizisinin kliniği ve yönetimi tartışılmıştır. Gereç ve Yöntem: Akut otitismedia nedeniyle kliniğimize başvuran yedi çocuk hastanın tıbbi bilgileri retrospektif olarak incelenmiştir. Bulgular: Yedi çocuğun (Yaş: 1-9 yıl; 3 kız, 4 erkek) tamamı miringotomi operasyonu geçirmiştir. Kortikosteroid ve antibiyotikler tedaviye eklenmiştir. Bütün çocuk hastalar sekelsiz iyileşmiş olup, iyileşme süreci 1 hafta ila 1 ay arasında farklılık göstermiştir(Ortalama iyileşme süresi: 1,8 hafta). Tartışma: Akut otitismedianın seyri esnasında uygun tedaviye rağmen fasiyal paralizi gibi nadir komplikasyonlar gelişebilir. Erken tedavi bu klinik durumu yönetmek için oldukça önemlidir.

Anahtar Kelimeler

Periferik Fasiyal Paralizi; Akut Otitis Media; Orta Kulak Hastalıkları; Supurasyon; Timpanik Membran

Abstract

Aim: Acute otitis media is a common disease among children, and peripheral facial nerve paralysis secondary to acute otitis media is a dramatic clinical entity for children and parents. In this report we discuss the clinical presentation of facial nerve paralysis secondary to acute otitis media and management of this clinical issue. Material and Method: The medical histories of seven children who suffered from facial nerve paralysis secondary to acute otitis media were collected retrospectively. Results: All seven of the children(ages: 1-9 years; 4 boys, 3 girls) underwent a myringotomy operation. Corticosteroids and antibiotics were also added during the treatment. All of the children were recovered totally; the recovery period varied from a week to a month(meanrecovery time: 1.8 weeks). Discussion: Rare complications like facial nerve paralysis can be seen during the normal course of acute otitis media,despite proper treatment. Immediate treatment may help to overcome these clinical complications.

Keywords

Peripheral Facial Nerve Paralysis; Acute Otitis Media; Middle Ear Disease; Suppurations; Tympanic Membrane

DOI: 10.4328/JCAM.4725

Received: 30.06.2016 Accepted: 09.08.2016 Printed: 01.03.2017 J Clin Anal Med 2017;8(2): 102-5

Corresponding Author: Ahmet Mutlu, KBB Anabilim Dalı, Kocaeli Üniversitesi Tıp Fakültesi, 41380, Umuttepe, Kocaeli, Turkey.

GSM: +905355003650 F.: +90 2623037003 E-Mail: ahmutlu1988@gmail.com

Introduction

Acute otitis media is a common disease in the pediatric population. Tube eustachian dysfunction,immature immune system,bacterial or viral loads, and genetic and environmental-factorsare suspected asthe causes [1]. Clinical aspects of this disorder can show a wide range from non-specificcomplaints to mortal intracranial complications. Misuse of antibiotics and anti-inflammatory medications may easily mask the symptom-samong the pediatric population [2]. Peripheral facial nerve paralysis (FNP) is a dramatic intratemporal complication for the patients and theirfamilies.

The co-existence of facial paralysis and acute otitis mediais rare.Modern medical care and efficient antibiotic therapies have decreased the frequency from0.5% to0.005% [3-5].In this report we aimed to discuss the pathophysiology and management of FNP secondary to acute otitis media in the pediatric population.

Material and Method

The objects of this study werethe children admitted to the Kocaeli University Faculty of Medicine Otorhinolaryngology Clinic from 2011-2015 for facial nerve paralysis secondary to acute otitis media. All data (medical history, examination and treatment notes, radiologic images) were acquired from the medical records retrospectively.The patients were examined by a consultant otolaryngologist and evaluated with the House-Brackmann (HB) facial grading system [6]. All of the children were assessed with multifrequency tympanometry (Interacoustics® AT235h, Assens, Denmark) and middle ear condition was classified according to Jerger’s classification [7,8]. The ethics committee ofKocaeli University Faculty of Medicine approved this study (KAEK-2015/271).

Results

Seven children with this clinical aspect were identified; none of them had any accompanying complications. There were four (57%) males and three females (43%). The mean age was 3.7 years (median: 3, min: 1, max: 9). Four patients (57%) were affected on the right side and three patients (43%) on the left. One child withHouse-Brackmann(HB) grade 2, four with HB grade 3, one with HB grade 4, and one with HB grade 5 were admitted at the first day of facial paralysis to theclinic. Upon otoscopic examination, six patients were found to have an opaque hyperemic tympanic membrane and air-bubble level behind the drum. All of the patients mentioned having used amoxicillin-clavulanate (600/42.9 mg)40-60 mg/kg polytherapyfor

the acute otitis mediabefore developing FNP. One patient had active suppuration in the external ear canal and micro perforations were detected on the tympanic membrane. None of the patients had a rash or a history of trauma. Three children had undergone myringotomyand four children had receivedventilation tube insertionwith myringotomyunder general anesthesia to drain off middle ear effusion within 24 hours of the facial paralysis onset.The patients in our study received antibiotic therapy (ampicillin-sulbactam 100 mg/kg/day iv) and systemic steroids (Methyl prednisolone 1mg/kg/day iv)postoperatively. The patients with HB grade 2 and 3 paralysis had a rapid recovery to grade 1 within seven days. Both of the patients with grade 4 and 5 paralysis improved to grade 2 within a week and recovered spontaneously to grade 1 within a month (Table 1). Radiological assessments were required for these two patients because the recovery was only partial. Temporal bone magnetic resonance images revealed neuritis on the tympanic segment of the facial nerve in the patient with grade 5 FNP; the other patient hadnormal findings (Figure 3).Neither of the patients required any further surgical intervention (mastoidectomy, facial nerve decompression, etc.).

Discussion

Acute otitis media is a common disorder in the pediatric population, especially in early childhood. Otolaryngologists, pediatricians, and family medicine physicians have an important role in diagnosis and proper medical management to prevent com-

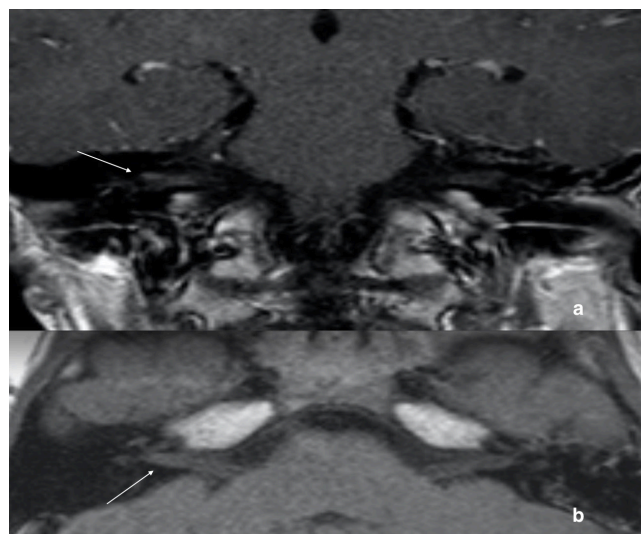


Figure 3. Increased intensity is revealed on the right facial nerve in temporal bone magnetic resonance (MR) images a) Coronal section of contrasted T1- weighted MR images b) Axial section of contrasted T1- weighted MR images; White arrow: Right facial nerve contrasted.

Table 1. General information of the patients. (M: Male, F: Female, HB: House-Brackmann Grade, BT: Before Treatment, AT: After Treatment, MRI: Magnetic Resonance imaging, VT: Ventilation Tube, My: Myringotomy).

Patient Number	Sex	Age (Year)	HB BT	HB AT (1 week)	HB AT (4 weeks)	MRI	Trauma	Systemic Disease	Treatment	Recurrent Paralysis
1	M	1	4	2	1	+	-	-	VT	-
2	M	2	3	1	1	-	-	-	VT	-
3	F	3	3	1	1	-	-	-	VT	-
4	F	3	3	1	1	-	-	-	My	-
5	F	4	2	1	1	-	-	-	My	-
6	M	4	5	2	1	+	-	-	My	-
7	M	9	3	1	1	-	-	-	VT	-

plications. Ineffective examination of children or inappropriate medical treatments may hide the symptoms of complications. Intracranial complications such as meningitis, intracranial abscess, and otitic hydrocephalus can be mortal, whereas intratemporal complications such as mastoiditis, FNP, and labyrinthitis are more benign conditions [9]. Sudden onset of peripheral facial nerve paralysis may be the most dramatic complication for the patients and their families. Poor eyelid closure, disabled movement of mouth angle, and insignificant nasolabial sulcus are the most frightening symptoms for peripheral facial nerve paralysis (Figure 1). The paralysis grade can be progressive according to the facial nerve injury and severity.

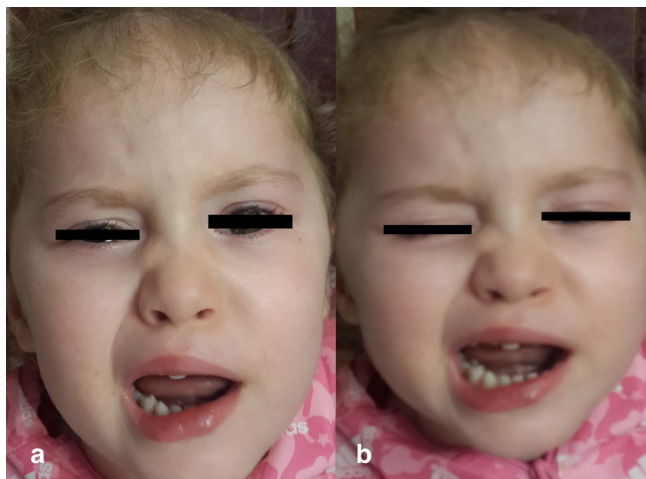

Figure 1. Facial nerve examination of a three-year-old girl: Left sided HB grade 3 peripheral facial nerve paralysis. a. Resting position, b. Disabled facial expression with effort.

It is vital to detect the possible reason for facial nerve paralysis when an otologic disorder is present. The clinical aspects of the FNP and the treatment modalities will be different when chronic otitis media co-exists [10]. In our study, all of the children were admitted with progressive symptoms of acute otitis media and suffered from severe ear pain despite of medical therapy. Otitoscopic findings of the patients—bulging hyperemic tympanic membrane and air-bubble levels (Figure 2)—show a correlation with acute otitis media. Only one patient had micro perforations on the tympanic membrane due to acute suppuration, but no history of chronic otitis media was determined.

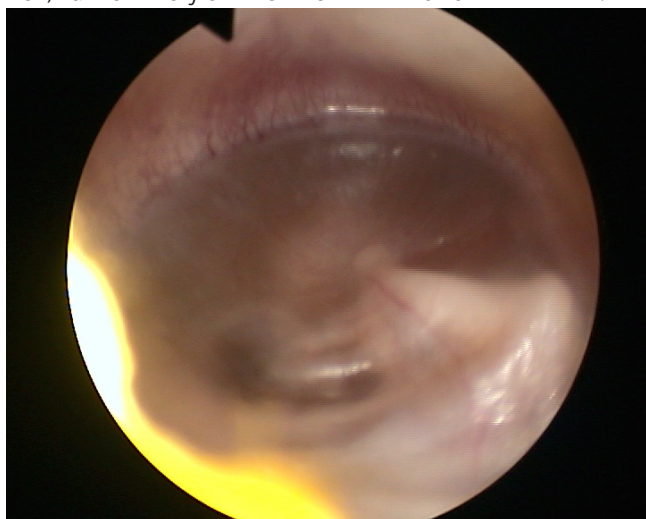

Figure 2. Bulging hyperemic tympanic membrane is revealed on the otoscopic examination (left ear).

Facial nerve paralysis prognosis can be predicted by electrophysiological studies; however, children can be uncooperative for these assessments. Total nerve paralyzes and incomplete progressive paralysis of the facial nerve are the indications for the electrophysiological studies. In our patients, electrophysiological studies were not considered because there was good facial nerve recovery due to our treatment.

Radiological studies can be helpful in determining the affected part of the facial nerve. Increased contrast on T1 weighted and T2 weighted Magnetic Resonance Images (MRI) is useful to identify facial neuritis. Middle ear effusion and mastoiditis also can be detected. Polat et al. showed the high false positivity rates of T2-weighted MRI and low correlation of mastoid fluid with acute mastoiditis [11]. Incomplete nerve recovery, total paralysis, and isolated facial nerve branch paralysis may be some of the indications for MRI. Uluat et al. reported that computerized tomography (CT) may be useful to identify bone dehiscence on tympanic, mastoid segments of the facial nerve canal and other mastoid bone problems such as coalescent mastoiditis and bone destruction [10]. The benefits of a CT scan must be weighed against the high radiation levels. We did not prefer CT scan in our population and only two children had a MRI scan because of their delayed recovery. MRI revealed neuritis on the tympanic segment of the facial nerve.

The consensus among most authors on facial nerve paralysis with acute otitis media is to use conservative treatment approaches. Broad-spectrum intravenous antibiotics must be considered as a first step [12]. Intravenously applied maximum dosage antibiotherapy may assure control of the infectious process and stop the bacterial proliferation. As the literature suggests, we applied antibiotics to all of our patients depending to their recurrent symptomatic middle ear effusions. Myringotomy with or without ventilation tube insertion may be indicated if the tympanic membrane shows symptoms of middle ear effusion. All our patients underwent myringotomy under general anesthesia to relieve the tympanic portion of the facial nerve and ventilation tubes were inserted in four of the patients because of the thick glue-like middle ear fluid. Microbial cultural sampling from the middle ear had not performed because of the antibiotic history of the all patients.

The facial nerve lies in the Fallopian canal. Bony canal dehiscences may be present but it is still not known how these dehiscences occur [13]. Recurrent inflammations or granulation tissue may erode a congenitally thin bony layer and microbial toxins may influence the facial nerve sheath. Epineurium edema can have effects ranging from partial weakness to total paralysis of motor functions. Steroids can pass into the inner ear fluids and may reach effective concentration levels in the ear [14]. For this reason, steroids are an effective medication to decrease facial nerve edema. In our study, all of the patients received a 14-day course of systemic steroids.

Facial nerve paralysis due to acute otitis media may recover within a few weeks with appropriate treatment, as mentioned above. However, a few patients may need surgical interventions like myringotomy with or without ventilation tube insertion. Myringotomy can eliminate the middle ear fluid, but cortical mastoidectomy, with or without facial nerve decompression, could be considered in few cases to control this disorder. Total facial

nerve paralysis (HB Grade 6), total axonal degeneration, or poor axonal regeneration rates as determined by electrophysiological studies are the indications for facial nerve decompression surgeries. Decompression surgery may be more effective when the operation is performed within 3 weeks after the onset of FNP [12]. None of our patients needed any of these procedures because of the benign courses of their facial paralysis.

Conclusion

Peripheral facial nerve paralysis associated with acute otitis media is a rare and dramatic condition in the pediatric population. Determining the precise reason for facial nerve paralysis can be challenging, but exact diagnosis is important. Certain medical treatment modalities are effective and surgical interventions may increase the rate of recovery.

Competing interests

The authors declare that they have no competing interests.

References

1. Rovers MM, Schilder AGM, Zielhuis GA, Rosenfeld RM. Otitis Media Lancet 2004;363:465-73.
2. Wu JF, Jin Z, Yang JM, Liu YH, Duan M. Extracranial and intracranial complications of otitis media: 22-year clinical experience and analysis Acta Oto-Laryngologica 2012;132:261-5.
3. Popovtzer A, Raveh E, Bahar G, et al. Facial palsy associated with acute otitis media. Otolaryngol Head Neck Surg 2005;132:327-9.
4. Ellefsen B, Bonding P. Facial palsy in acute otitis media. Clin Otolaryngol 1996;21:393-5.
5. Gaio E, Marioni G, Filippis C, et al. Facial nerve paralysis secondary to acute otitis media in infants and children. J Pediatr Child Health 2004;40:483-6.
6. House JW, Brackmann DE. Facial nerve grading system. Otolaryngol Head Neck Surg 1985;93:146-7.
7. Jerger J. Clinical experience with impedance audiometry. Arch Otolaryngol 1970;92(4):311-24.
8. Mutlu A, Durgut M, Ozturk M, Buday MC, Topdag M, et al. Comprehensive Study of 226-1000 Hz Multifrequency Tympanometry Measures in Infants. J Otolaryngol ENT Res 2015;2(4):00030.
9. Mutlu A, Buday C, Ozturk M, Almac A. A Rare Complication of Acute Otitis Media: Otitic Hydrocephalus J Clin Anal Med DOI:10. 4328/JCAM. 2295.
10. K Uluat A, Bayir Ö, Sancaktar ME, Özdek A, Tatar E. Ç, Saylam G, Korkmaz M.H. Facial Canal Dehiscence in Patients with Chronic Otitis Surgery. J Clin Anal Med 2015;DOI:10. 4328/JCAM. 3646.
11. Polat S, Aksoy E, Serin GM, Yildiz E, Tanyeri H. Incidental diagnosis of mastoiditis on MRI. Eur Arch Otorhinolaryngol 2011;268:1135-8.
12. Yonamine FK, Tuma J, Nunes da Silva RF, Soares MCM, Testa JRG. Facial paralysis associated with acute otitis media Braz J Otorhinolaryngol 2009;75(2):228-30.
13. Yetiser S. The dehiscence of the facial nerve canal. Int J Otolaryngol 2012;2012:679708.
14. Parnes LS, Sun AH, Freeman DJ. Corticosteroid pharmacokinetics in the inner ear fluids: an animal study followed by clinical application Laryngoscope 1999;109(7):1-17.

How to cite this article:

Mutlu A, Ozturk M, Topdag M, Iseri M, Dasli S. Peripheral Facial Nerve Paralysis Secondary to Acute Otitis Media. J Clin Anal Med 2017;8(2): 102-5.